



**PATIENT**

Jinx Blacken

**SPECIES**

Feline

**BREED**

DLH

**SEX**

Female Spayed

**AGE**

16 years

**WEIGHT**

9.66lbs

**INTERPRETED BY**

Maggie Machen  
Lamy, DVM, DACVIM  
(Cardiology)

**IMAGING  
PERFORMED BY**

Sara Hansen

**HOSPITAL NAME**

Santa Clara Animal  
Hospital

**REFERRING VET**

Dr. Elsbree

**INVOICE**

29714

**DATE**

3/20/23

**PRESENTING CLINICAL SIGNS**

History: Intermittent grade 3/6 heart murmur. Currently on Amlodipine for elevated blood pressure, which resolved when on medication. Has chronic kidney disease.

-Abnormal lab results: 2/10/23: SDMA - 17, Creatinine- 2.4. AFTER STARTING AMLODIPINE 2.5mg- 1/4 sid 1) 156/96 (113) HR 216 2) 150/84 (107) HR 211 3) 140/93 (114) HR 214 4) 148/90 (117) HR 204 5) 153/89 (115) AVERAGE: 149/90 (113) HR: 211 4/27/22: BEFORE STARTING AMLODOPINE 1) 203/113(158) HR 187 2) 200/122(156) 185 3) 206/113(158) 191 4) 208/113(155) 189 5) 204/113(159) 180 Average: 203/119 (15Heart Rate7)>

-Current medications: Amlodipine 2.5mg- 1/4 tb SID; marbofloxacin 25mg- 1/4 tb SID; tobramycin 0.3% drops in left eye bid; solensia monthly

**ECHOCARDIOGRAM FINDINGS**

2D, m-mode, color flow and doppler imaging is available. The left ventricular wall is normal in dimension. There is a diffusely hyperechoic endocardium consistent with age-related fibrosis. Minimal remodeling. The papillary muscles are hyperechoic. The left atrium is normal in size. The right atrium is normal in size. The right ventricle appears normal. The mitral valve is normal in structure and mobility. No MR. The tricuspid valve appears normal in structure and mobility. No TR. Blood flow through both the LVOT and RVOT are normal in velocity. No effusions. No obvious cardiac tumors.

**CARDIAC CHART**

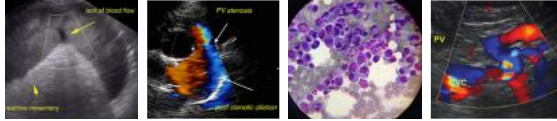
FELINE CARDIAC PARAMETERS	BODY WEIGHT (kg)	HR (BPM)	IVSd (cm) (Moise, Pipers)	LVIDd (cm) (Moise, Pipers)	LVWd (cm) (Moise, Pipers)	FS (%)	EF (%)
NORMAL PARAMETER	-----	150-240	0.35-0.55	<2 (mean 1.5)	3.5-0.55	35-67	80-100
PATIENT	4.4	NM	0.46	1.27	0.48	61	92
FELINE CARDIAC PARAMETERS	LA/AO (Boon)	LA/AO HEART BASE (Swe) (Abbott)	LA 2D short axis Base view (cm) (Abbott)		LVOT VEL (m/s)	RVOT VEL (m/s)	E max (m/s)
NORMAL	<1.5	<1.3	<1.2		<1.6	<1.3	<0.9
PATIENT	NM	1.2	1.1		0.81	0.84	NM

*\*Note: All measurements based upon multi-modal images and methods. An average value is reported.*  
Adapted from June Boon, Veterinary Echocardiography, 1998  
Abbott J & MacLean H JVIM 2006;20: 111-119, Moise et al. Am J Vet Res 47:1476, 1986. Pipers et al. Am J Vet Res 40:882, 1979.

**INTERPRETATION OF THE FINDINGS & FURTHER RECOMMENDATIONS**

Overtly normal geriatric cardiac structure and function. Mild fibrosis of the left ventricular wall is noted, which is likely a normal age-related variant. No significant valve leaks are noted, and flow through the great vessels is normal in velocity. No definitive cause is identified for the murmur in this study, making it likely physiologic in origin (i.e., secondary to tachycardia, volume changes, etc.). Given these findings and a normal LA dimension, no medications are indicated. No evidence of hypertensive cardiomyopathy.

No cardiac contraindication for general anesthesia. Should fluid or steroid therapy be indicated in the future, any cat should be monitored for intolerance (changes in RR/RE).



**PATIENT**

Jinx Blacken

Monitor at home for signs of cardiac compromise, including respiratory changes and/or signs of a blood clot event (paralysis, neurologic changes).

**SPECIES**

Feline

Recommend recheck echocardiogram in 1 year to assess for any progressive issues or development of disease the pre-existing murmur may mask.

**BREED**

DLH

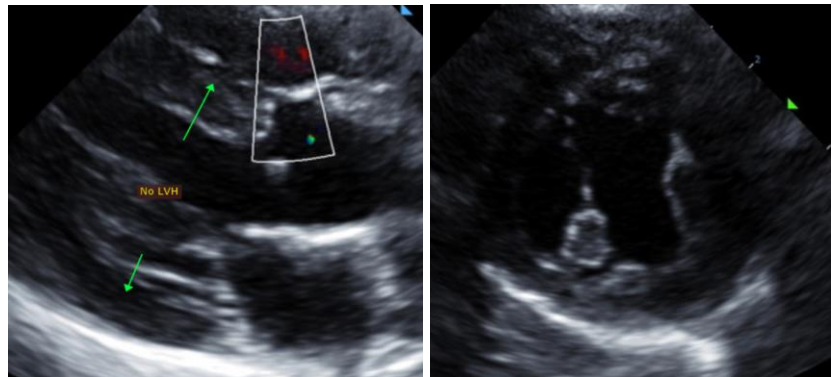
**SEX**

Female Spayed

**AGE**

16 years

**IMAGES**



**WEIGHT**

9.66lbs

The information and recommendations provided are based on the images presented by the referring veterinarian. No evaluation can be communicated regarding pathology that was not visible in the image/video clips provided.

**INTERPRETED BY**

Maggie Machen  
Lamy, DVM, DACVIM  
(Cardiology)

Thank you for this referral. This report was generated using transcription software, and minor dictation errors may be present. If the clinical or image interpretation does not parallel your findings or if I can be of any further assistance, please contact me.

**Maggie Machen Lamy, DVM**  
Diplomate of the American College of Veterinary Internal Medicine (Cardiology)  
info@sonopath.com

**IMAGING PERFORMED BY**

Sara Hansen

**HOSPITAL NAME**

Santa Clara Animal  
Hospital

**REFERRING VET**

Dr. Elsbree

**INVOICE**

29714

**DATE**

3/20/23